



PREPARED BY:

Athena Papas, DMD, PhD, Head of Division of Oral Medicine and Public Health Research, Johansen Professor of Dental Research, Tufts University School of Dental Medicine.

Mabi Singh, DMD, MS, Director of Oral Medicine and Dry Mouth Clinic and Associate Professor, Tufts University School of Dental Medicine.

Cancers of the head and neck, which include cancers of the oral cavity, larynx (voice box), pharynx, salivary glands, and nose/nasal passages, account for approximately 3 percent of all malignancies in the United States. Cancers of salivary glands, muscle, bone, brain, eyes, skin, and thyroid glands are not usually classified as cancers of head and neck. The incidence of head and neck cancer is approximately 15 per 100000 and declining.

It is estimated that approximately \$3.1 billion is spent in the United States each year on treatment for head and neck cancers. Treatments may include surgery, chemotherapeutic agents, antiangiogenesis agents, photodynamic therapy, laser therapy, radiation therapy or combination of these.

The prevention and screening of known risk factors, promotion of the good oral health and dietary behaviors have aided in the declining trend of head and neck cancer prevalence. Early detection and diagnosis, and better treatment options have aided in decreasing related mortalities. However, some treatments result in short-term and long-term side effects and complications, some of which directly involve the oral cavity. This discussion is limited to oral complications of radiation therapy and potential methods to reduce them.

The main objective of the therapeutic radiation (RT) is to achieve the cellular death of the cancer cells. In the process, the normal structures surrounding the cancer and which are in the path of radiation are also affected.

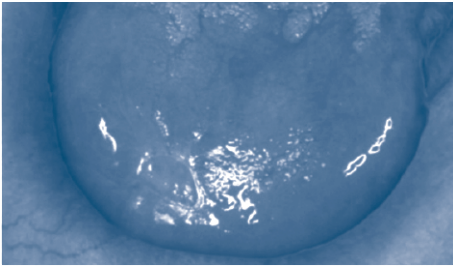
It is necessary that a dentist be part of the team treating a patient who is undergoing RT in the head and neck region. RT has a variety of immediate and long-term side effects depending upon the dosage, fraction size, field and type of radiation. Types of radiation include intensity modulated radiation therapy, (IMRT) and external beam ionizing radiotherapy, which is the most common for head and neck cancers. Patients generally undergo RT for three to seven weeks, with sessions five days a week. Depending on the type and nature of the pathology, the total dosage of radiation may range from 3000- 7000 cGy or more.

Pre-Radiation Assessment

Prior to the beginning of radiation, a comprehensive oral exam should be done, including whole mouth periapical radiographs and a panoramic radiograph. The aim of this exam is to find any potential sources of irritation, infection, and any pathology that would cause problems during or post-radiation. Vitality of the suspected teeth should be checked and any extraction should ideally be done 10-14 days prior to the beginning of radiation to provide sufficient time for healing.

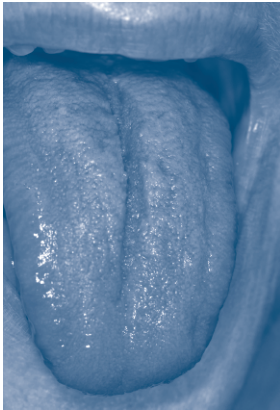
The following guidelines can be used in considering teeth for treatment or extraction:

- Irritation caused by sharp edges of teeth, orthodontic brackets, defective restorations, or defective prosthesis should be corrected.
- Carious lesions and recurrent carious lesions should be restored.
- Deep pits and fissures should be sealed to reduce the probability of carious lesions in future.
- Any carious lesions that potentially threaten pulpal integrity should be treated with endodontic therapy or extracted.
- Any periapical lesions greater than the diameter of 3 mm in diameter radiographically should be considered for extraction, however, periapical lesions less than 3 mm diameter should be endodontically treated. If the prognosis of endodontics is poor, it is better to extract the teeth.
- Patients with calculus build up and deep pockets should be treated with scaling and root planing.
- If pocket depths exist which are more than 5-6 mms, extraction of the involved teeth should be considered.
- Teeth with root furcation involvement (Class II) should also be considered for extraction as the teeth can become sources of infection.
- Non strategic teeth (e.g., not in occlusion) should be considered for extraction.
- Teeth with mobility greater than 2 should be considered for extraction.



Radiation and Chemotherapy combined

A thorough prophylaxis is recommended (if patient has not had one in past 3 months) along with weekly application of fluoride varnishes if there is any evidence of incipient decay.

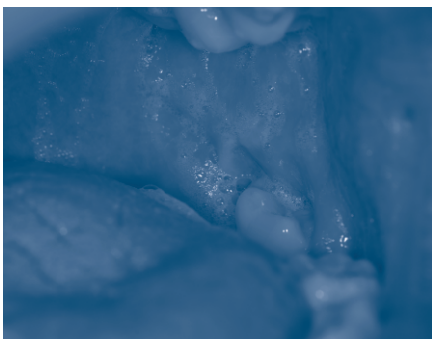


Coated tongue

Prescription strength fluoride toothpaste should be prescribed along with the use of MI Paste Plus. Patients should be educated and informed of the potential short and long-term side effects of therapeutic radiation. A sialogogue (Pilocarpine 5-7.5 mg or Cevimeline 30 mg, TID-QID as tolerated) should be prescribed, including 1 tablet/capsule taken one hour prior to radiation. Caphosol® or Neutrosol® rinses QID can be used for remineralization and prevention of mucositis.

During the Therapeutic Radiation

Depending upon the type and location of cancer, the dosage and field of radiation varies. Alteration of taste may begin early on in the treatment, with symptoms possible at 200-1000 cGy. With an increasing dosage of radiation, the mucosa of the oral cavity becomes hyperemic, edematous, pseudomembranous and necrosis occurs at the basal layer and may become ulcerated. The dead tissue can become a feeding ground for bacteria and candida and the population can increase exponentially (e.g. streptococcus mutans and lactobacilli, 10^3 to $> 10^6$ CFU) which is accentuated by loss of protective antimicrobial functions of saliva. Due to loss of lubrication and diluting properties of saliva, which can start at 800-1000 cGy, speaking and swallowing becomes a difficult task. Levels of pain depend upon the degree and extent of mucositis and ulceration, and can often lead to the patient needing pain medication and an alternative method of feeding (e.g., PN or gastric tube). The discomfort, irritation, pain and difficulty in chewing and swallowing can potentially lead to malnutrition and substantial weight loss. Food may need to be ground to ease swallow-



Frothy Saliva

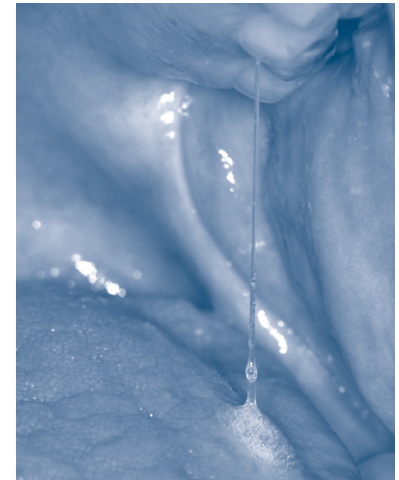ing, and may need to be served at room temperature or cooled. Extra nutritional supplements are often given via gastric tube. Frequent feedings are important also maintaining the swallowing during radiation therapy is important.

The lateral borders of the tongue, lips, soft palate, buccal mucosa and floor of the mouth are most susceptible to mucositis. The severity of mucositis dictates the treatment, e.g., cryotherapy (ice chutes), application of topical anesthesia, and/or analgesics (including narcotics).

Secondary infections are common occurrences and may include candidal, bacterial and viral infections. In the case of persistent candidiasis, use of antifungals such as nystatin oral rinses, clotrimazole troches (only after RT) or systemic azoles (e.g., fluconazole) may be necessary. To minimize super infections during RT, the use of saline and baking soda rinses may help wash away bacteria, candida and dead tissue. These rinses can also neutralize pH in the oral cavity especially when oral hygiene is an issue, and the oral cavity becomes acidic. A decline of 50-70% of the original salivary volume, a subjective sensation of dryness in the oral cavity is perceived (xerostomia). With continued and irreversible destruction of the acinar and serous salivary gland cells, the salivary characteristics changes to thick, viscous, ropy, mucus with loss of immunological components.

Post Therapeutic Radiation

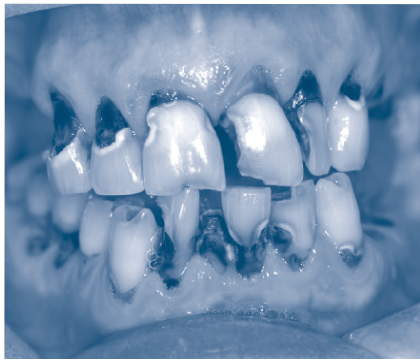The side effects of RT depend on the field, dosage, and radiation fraction. Even though muscle tissue is resistant to radiation it may be affected and cause limited opening of the mouth (trismus). Impairment of blood supply to the temporomandibular joint, masticatory muscles and salivary glands can have a deleterious effect on masticatory process. RT in children may hinder the normal growth and development resulting in maxillofacial deformity, hypodontia and developmental defects in the permanent teeth.



Think, viscous, ropy saliva post-radiation

Decreased perfusion of tissues continues progressively because of the hyalinization of the blood vessels and fibrosis.

The qualitative and quantitative loss of saliva results in xerostomia, diminished clearance of carbohydrate substrate, increased cariogenic bacterial and candidal populations, decreased potential of remineralization and increased demineralization to bacterial and dietary acids. The diminished pellicle formation on the tooth surface also makes the dentition



Severe decay post-radiation

vulnerable to direct contact with acids resulting in tooth surface loss. Also due to the lack of saliva or its lubrication function, opposing tooth surfaces results in increased attrition and tooth-paste abrasion. To overcome these problems, patients

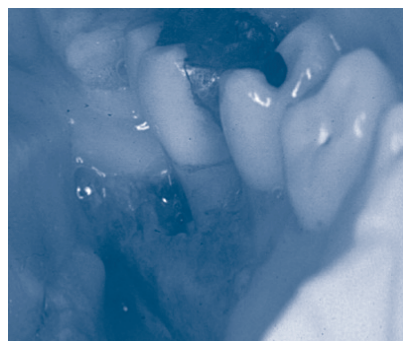
should restrict frequency and contact duration of acidic drinks. They should be advised not to brush immediately after acidic challenges when the tooth surfaces lose micro-hardness. Rinsing with a low (300ppm) fluoride containing rinse, baking soda rinse (1 tsp. baking soda in 8 oz. water), water or milk may restore pH to normal level as buffering capability of saliva is decreased.

Due to disruption in "caries balance", primarily because of salivary hypofunction and consequent loss of protective factors of saliva, loss of minerals from teeth is rapid. The decrease in unstimulated (resting) saliva to 0.1ml/min (normal = 0.3ml/min) is principally due to reduction in flow from the submandibular and sublingual glands which are supersaturated with calcium and phosphates. This lessens the reuptake of the minerals and reduces the remineralization potential. The altered enamel and dentinal structures due to radiation, not necessarily in the field of radiation, become vulnerable, and resistance to bacterial acidic challenges is reduced. The microenvironment in the oral cavity becomes conducive for formation of carious lesions. Therefore, carious lesions are formed even at non-plaque retentive areas, e.g., cusp tips and incisor edges of the maxillary teeth, where the fluid film is the least. Plaque retentive smooth surfaces and deep fissures are also prone to develop carious lesions. The threat of increased carious lesions and failures of restorations remains for life.

Overcoming risk factors for carious lesions is a lifelong challenge. In our experience, patients are not well educated in advance about the preventable potential complications. Plaque removal with meticulous oral hygiene must be emphasized. Daily use of prescription strength fluoride toothpaste (5000 ppm) (without rinsing after) and the application of Ca and PO₄ in supersaturated state (rinse or paste in phosphopetide) soluble glass remineralizing agents are recommended. Sialogogues (Pilocarpine or Cevimeline) should be titrated to the maximum dose that the patient can tolerate without side effect. Chewing gum with xylitol may be helpful for gustatory and mechanical stimulation and will increase production from remaining functional salivary glands. This increased salivary flow will clear carbohydrate substrate, dilute the acidity in the oral cavity and wash away microbial population. Thereby, decreasing demineralization and increasing remineralization. Suggestion of salivary substitutes should be done with caution, and pH of the products should be confirmed. Brushing tongue can reduce the rate of development of biofilm on soft and hard tissue of oral cavity.

Keeping a humidifier in the room, set at (least) 50%, especially at night will help reduce moisture loss from the oral tissue from breathing at night. Breaking Vit E capsules can provide some lubrication.

Standard of care for dental visits should be every three months. These visits should include a prophylaxis, application of 5% fluoride varnish, and examination of tooth surfaces for tooth surface loss and carious lesions. Carious lesions should be recorded to note any progression or reversals. The frequency of taking radiographs, including panoramic, should be increased to once a year as these patients are deemed "high risk" and carious lesions progress very rapidly in salivary hypofunction patients. Also, the oral cavity should be examined for candida and bacterial count. There is a positive association between salivary hypofunction and candida. There is growing evidence of candida lowering the oral pH and having a positive association with carious lesions. The patient's compliance to the at home regimens should be confirmed and re-emphasized at each visit.



Osteoradionecrosis

Chances of soft tissue necrosis and osteoradionecrosis cannot be undermined. The soft tissue and bone become hypovascular, hypocellular and hypoxic at the site or at distant area from radiation. The capillary density continues to decrease and spontaneous necrosis of soft

and bony tissue can result without any insult or injury to the area. Areas of non-healing ulcers or exposed bony lesions may be observed or reported. They most commonly occur in the lingual aspect of mandible posterior to the dentition, due to the thickness of the bone and thin overlying mucosa. Also, tooth/teeth extraction, invasive periodontal procedures and (intrabony) prosthetic appliances can induce soft tissue and osteonecrosis due to high mandibular bone density and lack of collateral supply. Soft tissue and osteonecrosis are susceptible to developing serious secondary infections that may be painful, have suppuration and/or sequestration, and can cause pathological fractures. Treatment can range from rinsing with saline, oral and/or IV antibiotics, removal of sequestrum, bleeding of tissue to more extensive surgical intervention. Obtaining information from a radiation oncologist regarding field, dosage and type of RT will determine whether any dental procedure requires hyperbaric oxygen treatment (HBO) to prevent complications.

Patient at Home Regimen During and Post-Radiation

- Brush teeth with prescription fluoride toothpaste (do not rinse afterwards). At night brush ½ hour before bedtime.
- Apply MI Paste Plus 3-4 times a day and directly before going to bed.
- Do not brush immediately after meals. Brushing may increase the risk of tooth surface loss.
- Rinse with Caphosol®, Neutrasol®, or plain water with baking soda rinse (1tsp baking soda in 8 oz. water) after meals and snacks.
- Chew gum containing xylitol throughout the day. A piece of chewing gum in the mouth can stimulate salivary flow from remaining functional glands in case of TMJD.
- Brush teeth and tongue with powered (sonic) toothbrush with gentle pressure.
- Use a prescription sialogogue (Pilocarpine or Cevimeline) up to 3-4 times/day. Also, during radiation treatment, take a tablet/capsule 1 hour prior to treatment.
- Low fluoride containing rinse after meals (especially after acidic meals).
- Post-radiation— Break Vitamin E capsules in mouth, swish and spit up to 3 times a day. Keep a humidifier in the room set at 50% at night.
- Use other sugar/alcohol free oral comforting over the counter agents if relief is perceived.
- Visit the dentist every three months for a complete exam, cleaning, and topical fluoride treatments.
- Restore teeth as soon as carious lesions appear.
- Frequent large sipping or drinking of water does not help relieve dryness of the oral cavity. Try taking small sips to wet the oral mucosa which gives the sensation of wetness in the gum mouth and does not wash away salivary proteins.

Author Biographies

Athena Papas, DMD, PhD, Head of Division of Oral Medicine and Public Health Research, Johansen Professor of Dental Research, Tufts University School of Dental Medicine in Boston, Massachusetts

Dr. Athena Papas is the Erling Johansen Professor of Dental Research and the Head of the Division of Oral Medicine and Public Health Research at Tufts University School of Dental Medicine in Boston, Massachusetts. With expertise in the oral healthcare of the elderly and the medically compromised, Dr. Papas has devoted most of her professional career to this area of study and treatment. She specializes in the care of cancer, bone marrow transplant, geriatric, Sjögren's syndrome, xerostomic and medically compromised patients. She is a member of the medical advisory board of the Sjögren's Syndrome Foundation. Dr. Papas is a member of more than 15 professional organizations including The American Academy of Oral Medicine and The American Society of Geriatric Dentistry. Dr. Papas is a reviewer for Journal of Dental Research, Special Care in Dentistry, The New England Journal Of Medicine, Community Dentistry and Oral Epidemiology, along with 5 other journals. She has been the Dental Chairperson for the Massachusetts Public Health Association, a member of the professional advisory board for the Sjögren's Syndrome Foundation, Inc., former Dental Director of the New England AIDS Education & Training Center, in addition to participating in 14 other organizations. Dr. Papas has been the principal investigator of over 30 clinical trials and co-investigator of many more studies. In 2009, Dr. Papas was selected as the recipient of the International Association of Dental Research (IADR) Pharmacology-Therapeutics-Toxicology Research Award and is currently the President of PTT.

Mabi Singh, DMD, MS, Director of Oral Medicine and Dry Mouth Clinic and Associate Professor, Tufts University School of Dental Medicine in Boston, Massachusetts

Dr. Singh came from Nepal to the US in 1997. In Nepal, he worked as a general dentist and single handedly treated patients in the field. Dr. Singh has completed his Masters of Science in Dental Research and has worked on numerous research projects including NIDCR studies, and both industry and NIH sponsored Phase I-III clinical trials. Many of the research participants have come back to participate in other studies because of the relationship they have built with Dr. Singh.

His compassion for patients, strong clinical skills and knowledge are evident through his work in the Oral Medicine Clinic. He works with medically compromised patients suffering from autoimmune diseases, especially Sjögren's syndrome, radiation therapy patients with osteoradionecrosis of the jaw, BRONJ and HIV. He is very knowledgeable about the conditions and displays great clarity when explaining treatment options.

Dr. Singh has been doing the necessary preventive, restorative and other prosthetic dental work for all of the oral medicine studies and in the clinic, especially for the pre- and post-therapeutic radiation and hematopoietic stem cell patients, with excellent results.

References: <http://www.cancer.gov/cancertopics/treatment/head-and-neck>, <http://www.nidcr.nih.gov/OralHealth/Topics/CancerTreatment/HeadNeckRadiation.htm>, <http://www.mdanderson.org/patient-and-cancer-information/care-centers-and-clinics/care-centers/head-neck/index.html>, Shiboski CH, Hodgson TA, Ship JA, Schiødt M. Management of salivary hypofunction during and after radiotherapy. *Oral Surg Oral Med Oral Pathol Oral Radiol Endod* 2007; 103 (suppl 1): S66.e1-S66.e19. Jellema AP, Slotman BJ, Doornaert P, et al. Impact of radiation-induced xerostomia on quality of life after primary radiotherapy among patients with head and neck cancer. *Int J Radiat Oncol Biol Phys* 2007; 69(3): 751-60. Sonis ST, Elting LS, Keefe D, et al. Perspectives on cancer therapy-induced mucosal injury: pathogenesis, measurement, epidemiology, and consequences for patients. *Cancer* 2004; 100 (9 Suppl):1995-2025.

Join Our Community!



Provided by Eastern Dentists Insurance Company (EDIC), June 2012. The information contained is only accurate to the day of publication and could change in the future.